



Expression of aquaporin-4 in human supratentorial meningiomas with peritumoral brain edema and correlation of VEGF with edema formation

P. Wang¹, R.Y. Ni¹, M.N. Chen², K.J. Mou³, Q. Mao¹ and Y.H. Liu¹

¹Department of Neurosurgery, West China Hospital, Sichuan University, Chengdu, P.R. China

²Laboratory of Molecular Neurobiology, State Key Laboratory of the Biotherapy, West China Hospital, Sichuan University, Chengdu, P.R. China

³Department of Neurosurgery, Xinqiao Hospital, Third Military Medical University, Chongqing, P.R. China

Corresponding author: Y.H. Liu
E-mail: liuyanhui9@gmail.com

Genet. Mol. Res. 10 (3): 2165-2171 (2011)

Received December 15, 2010

Accepted May 14, 2011

Published September 23, 2011

DOI <http://dx.doi.org/10.4238/vol10-3gmr1212>

ABSTRACT. Peritumoral brain edema is a common complication of meningiomas. It is believed that vascular endothelial growth factor (VEGF), as an angiogenic factor, plays a vital role in edema formation. Aquaporin-4 (AQP4) is a small integral membrane protein that regulates water in the normal brain. However, the expression of AQP4 and its relationship to VEGF in edematous meningiomas are not well known. We studied tumor specimens of 59 human supratentorial meningiomas. Western blot analysis was used to detect the expression of AQP4, and double-labeling immunofluorescence histochemical staining was performed to determine the relationship between AQP4 and VEGF. The AQP4 expression was significantly higher in the edema group, in which the protein level was correlated

with the extent of edema. Greater VEGF expression was also observed in the edema group, and a relationship between AQP4 and VEGF was found. We conclude that AQP4 is involved in peritumoral brain edema formation in meningiomas and is also closely related to the expression of VEGF.

Key words: Meningiomas; Peritumoral brain edema; Aquaporin-4; Vascular endothelial growth factor

INTRODUCTION

Peritumoral brain edema (PTBE) is considered to be an important complication of meningiomas, which are the most common primary intracranial tumors in adults (Campbell et al, 2009). Approximately 60% of patients with meningiomas have PTBE, which can increase the mass effect of the tumor, aggravate clinical symptoms, raise intracranial pressure, and as a result lead to cerebral herniation (Bitzer et al., 1997a,b). Vascular endothelial growth factor (VEGF) has the ability to induce angiogenesis and increase vascular permeability, which is an important factor in the formation of PTBE in meningiomas (Kalkanis et al., 1996; Goldman et al., 1997; Provias et al., 1997; Bitzer et al., 1998; Machein and Plate, 2000; Otsuka et al., 2004; Ding et al., 2008).

Aquaporin-4 (AQP4) is a small integral membrane protein that can regulate brain water balance (Jung et al., 1994; Tait et al., 2008). It is reported that AQP4 is increased in some edematous brain tumors, such as astrocytomas and metastatic adenocarcinomas (Saadoun et al., 2002). However, little is known about the expression of AQP4 and its relationship to VEGF in meningiomas with PTBE. The objective of this research was to investigate the expression of AQP4 and VEGF and the relationship between AQP4 and edema extent in edematous supratentorial meningiomas.

MATERIAL AND METHODS

Patients

Fresh tumor specimens were collected from 59 patients with supratentorial meningiomas (WHO grade I) proven by two independent experienced pathologists. All patients had three-dimensional MRIs with contrast enhancement and were divided into two groups depending on edema index (EI) (see below) as follows: edema group (EI >1) and non-edema group (EI = 1) (Bitzer et al., 1998; Otsuka et al., 2004). The patients who suffered from other diseases that can cause brain edema or had preoperative steroid therapy were excluded.

Calculation of edema index

Based on axial images, the longest diameter of tumor (L_1) was determined on T1-weighted image (T1WI) with enhancement and the longest diameter of edema and tumor (L_2) on T2-weighted image (T2WI). The width vertically crossing the long diameter (W_1 , W_2) and the number of tumor layers (S_1 , S_2) were also measured. The volumes were calculated by $V = \Pi / 6 \times L \times S \times N$, and EI were defined as $EI = V_2/V_1$ (Bitzer et al., 1998; Otsuka et al., 2004).

Tissue preparation

Each specimen was divided into two equal pieces, where one was rapidly frozen in liquid nitrogen for later Western blot analysis and the other stored at -80°C for immunofluorescence staining of frozen sections.

Western blot analysis

Tissue pieces were homogenized with an ultrasonic cell disruptor, and extracted proteins were recovered after high-speed centrifugation and quantitatively determined using a BCA kit and ELISA analyzer. After separation via SDS-polyacrylamide gel vertical electrophoresis (160-180 V, 1 h), the proteins were transferred onto PVDF films. They were then rinsed in phosphate-buffered solution (PBS, 0.01 mM, pH 7.2-7.4) three times, each time for 5 min, and blocked with 5% evaporated milk for 1 h. AQP4 antibody (1:200; Santa Cruz Biotechnology, Inc., USA; sc-32739) was added, and the films were shaken at 4°C overnight. After washing in Tris-buffered saline Tween-20 (TBST, 1X) three times, they were incubated with HRP-labeled anti-mouse IgG (1:5000; Pierce, USA; 31430) on a shaker at 37°C for 1 h. Afterwards, they were again washed in TBST three times, and an ECL detection system was used to measure the bands with β -actin as the internal control, resulting in AQP4/ β -actin values.

Double-labeling immunofluorescence histochemical staining

Tissue samples were fixed in paraformaldehyde solution (40 g/L, 4°C) for 24 h and in sucrose paraformaldehyde solution (20%) for 4 h, and then immersed in sucrose solution (30%) for dehydration. After the tissues were dehydrated, frozen sections with a thickness of 10 μm were prepared. The slices were rinsed in PBS (0.01 mM, pH 7.2-7.4) three times, 5 min each, and incubated in goat serum (10%, 37°C) for 1 h. Afterwards, the tissues were again rinsed three times in PBS. The slices were incubated with AQP4 antibody (rat anti-human, 1:250; Santa Cruz Biotechnology) at 4°C overnight. The slices were similarly rinsed in PBS and then incubated with VEGF antibody (rabbit anti-human, 1:250; Wuhan Boster Biological Technology, Ltd., China; BA0407) at 4°C overnight. The slices were again similarly rinsed in PBS, and then the slices were incubated at 37°C for 1 h adding fluorescent-labeled secondary antibody (anti-mouse, red, 1:2000; Invitrogen Company, USA; GBA11020/46479A and anti-rabbit, green, 1:1000, Invitrogen Company; GBA11008). The slides were then rinsed three more times in PBS, mounted and then examined with an inverted fluorescence phase-contrast microscope. Five random visual fields (200X) were captured in positive areas. Goat serum and PBS were used as parallel controls. The number of positive and negative cells was determined for each field, and the percentage of positive cells was calculated.

Statistical analysis

All data are reported as means \pm SEM and analyzed with the SPSS 13.0 statistical software ($\alpha = 0.05$; $P < 0.05$ indicates statistical significance). Each index was submitted to a normality test. The *t*-test was adopted in the comparison of two sets and the Pearson correlation analysis was applied in the correlation analysis.

RESULTS

Edema index

According to MRIs, 40 patients had brain edema ($EI > 1$), whereas 19 patients had no brain edema ($EI = 1$). Typical images are displayed in Figure 1.

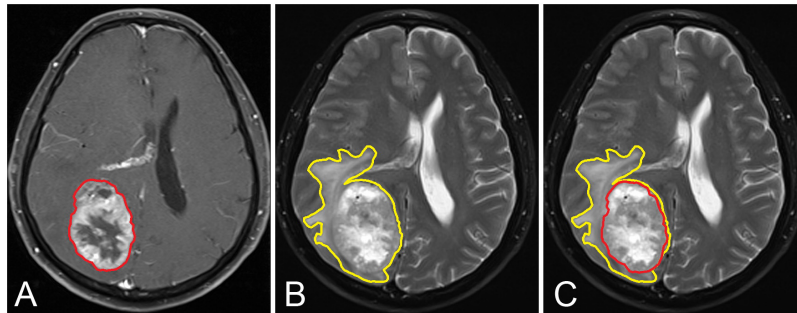


Figure 1. MRI of a meningioma with remarkable peritumoral brain edema. **A.** T1WI with contrast medium showed an enhanced tumor surrounded by a red line. **B.** T2WI showed a tumor with edema surrounded by a yellow line. **C.** The contrast of tumor and peritumoral brain edema in T2WI.

Western blot analysis

Western blot analysis showed that the expression of AQP4 was significantly greater in the edema group compared with the non-edema group (Figure 2A,B; $t = 3.73$, $P < 0.001$). According to the scatter diagram, protein level changed in the same direction with EI, and the Pearson correlation analysis demonstrated a positive correlation (Figure 2C; $r = 0.719$, $P < 0.001$).

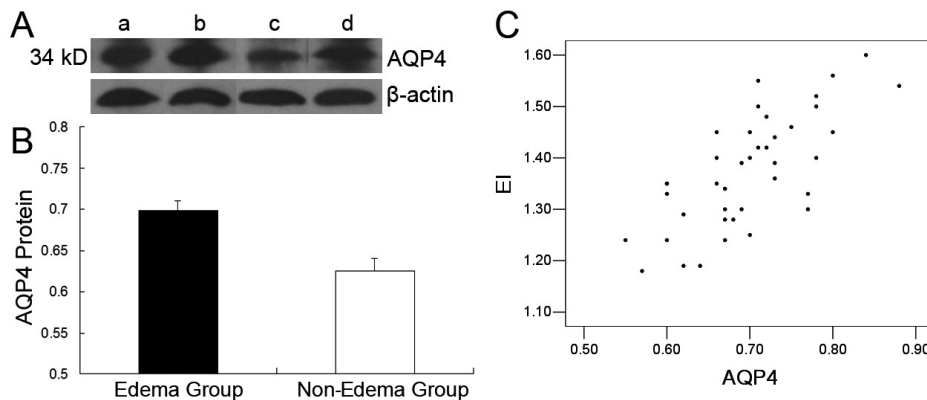


Figure 2. Aquaporin-4 (AQP4) protein expressed in meningiomas detected by Western blot technique. **A.** Expressions of AQP4 protein in meningiomas in the edema group (lanes *a*, *b*) and in the non-edema group (lanes *c*, *d*). **B.** Densitometry shows increased expression of AQP4 protein in the edema group ($t = 3.73$, $P < 0.01$). **C.** Scatter diagrams show a positive relationship between AQP4 protein and edema index (EI) in the edema group.

Immunofluorescence histochemical staining

In double-label staining, AQP4 expressed as red fluorescence and VEGF as green fluorescence were observed in the edema group (Figure 3B,D) and non-edema group (Figure 3A,C). The fraction of positive cells was increased for both AQP4 and VEGF in the edema group (Figure 4A; $t = 13.0$, $P < 0.001$; Figure 4B; $t = 8.72$, $P < 0.001$). Yellow fluorescence was displayed indicating that there was overlapping of AQP4 and VEGF expression (Figure 3E,F).

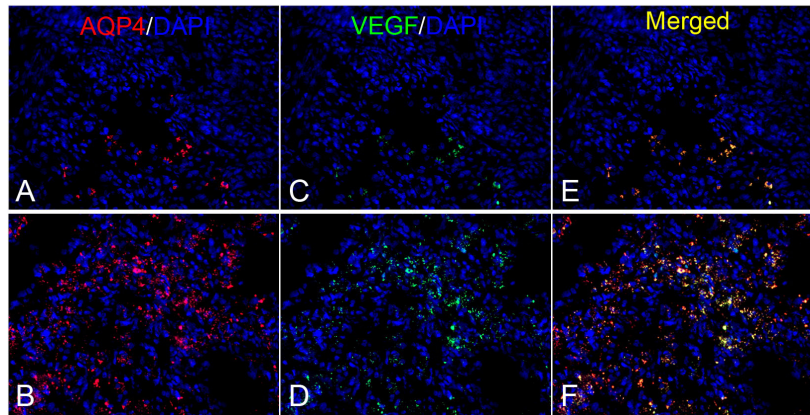


Figure 3. Expressions of AQP4 (red) and VEGF (green) detected by immunofluorescence technique. **A.** Expression of AQP4 in the non-edema group. **B.** Expression of AQP4 in the edema group. **C.** Expression of VEGF in the non-edema group. **D.** Expression of VEGF in the edema group. **E.** The merging (yellow) of AQP4 and VEGF in the non-edema group. **F.** The merging of AQP4 and VEGF in the edema group (200X). AQP4 = Aquaporin-4; VEGF = vascular endothelial growth factor; DAPI = 4'6-diamidino-2-phenylindole.

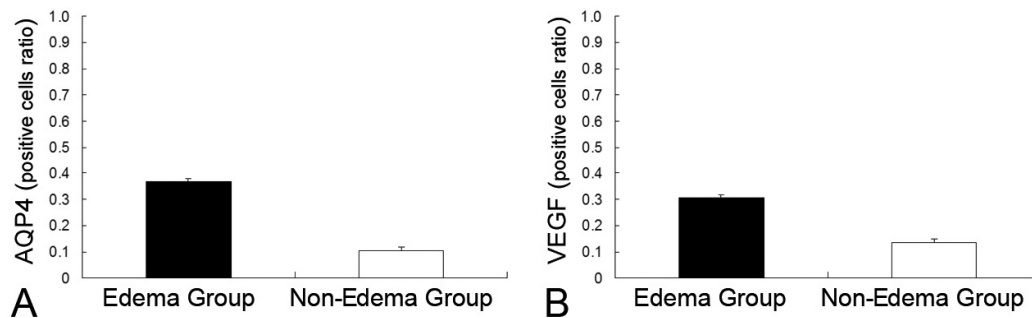


Figure 4. Positive cell fractions of Aquaporin-4 (AQP4) and vascular endothelial growth factor (VEGF) detected by immunofluorescence technique in edema and non-edema groups. **A.** Positive cell fraction of AQP4 is increased in the edema group. **B.** Positive cell fraction of VEGF is increased in the edema group.

DISCUSSION

Brain edema is mainly classified into cytotoxic edema and vasogenic edema. The major difference between them is whether there is breakdown of the blood-brain barrier (BBB) (Klatzo,

1994). In cytotoxic edema, cells swell because of malfunction of Na^+/K^+ -ATPase and sodium retention, but BBB is intact. In vasogenic edema, the integrity of BBB is disrupted, allowing water and other cellular components to occupy the intercellular space. PTBE of meningiomas is considered to be an example of vasogenic edema (Ide et al., 1992; Yoshioka et al., 1999).

AQP4 is a small hydrophobic integral membrane protein that is predominantly distributed in the central nervous system and acts as a regulator of water balance for the cell (Jung et al., 1994; Tait et al., 2008). In the human brain, it is chiefly located at the boundaries of parenchyma such as perimicrovessel astrocyte foot processes, glia limitans and ependyma, which suggests that AQP4 may affect water content in the brain (Tait et al., 2008). In some brain tumors, such as astrocytomas and metastatic adenocarcinomas, AQP4 is believed to be involved in the formation of brain edema (Saadoun, et al., 2002). In the present research, of 59 meningioma cases, we found that the expression of AQP4 was significantly greater in the edema group, and a positive correlation was established between the expression of AQP4 and EI, which indicates that AQP4 probably participates in edema formation around meningiomas. These outcomes corroborate the findings of Ng et al. (2009), who studied 17 cases of meningiomas and found that overexpression of AQP4 was associated with significant peritumoral edema; however, the relationship between AQP4 and VEGF was not mentioned.

VEGF has the ability to induce angiogenesis and increase vascular permeability (Machein and Plate, 2000). As early as 1996, Kalkanis et al. found that there was a marked enhancement of VEGF expression in patients with edema, which suggested that VEGF expression is an important factor in the etiology of edema around meningiomas. This theory was confirmed by other researchers (Goldman, et al., 1997; Provias, et al., 1997; Bitzer, et al., 1998; Otsuka, et al., 2004). Recently, strong evidence displayed that VEGF can penetrate peritumoral tissue and induce edema. Ding et al. (2008) reported that VEGF and VEGF mRNA were simultaneously expressed with positive correlation to edema in meningiomas, but only VEGF was positive in peritumoral areas without detection of VEGF mRNA. In VEGF-positive cases, a decreasing gradient of VEGF protein expression was also observed with increasing distance from tumors.

Here, expressions of AQP4 and VEGF were measured together, which demonstrated that both were upregulated in the edema group. A positive relationship between them was found with double-immunofluorescence histochemistry staining. This discovery suggests that AQP4 and VEGF probably act together in the process of PTBE formation. It was regretful that peritumoral tissues were not obtained in our experiment. Consequently, the expression of AQP4 in peritumoral areas is unclear. It is appreciated that AQP4 can be detected in these areas in animal models.

In conclusion, our results suggest that AQP4 may play a role in peritumoral brain edema formation around meningiomas and probably correlates with VEGF in the edema process. Although the exact mechanism of AQP4 upregulation in edematous meningiomas is still unclear and should be studied in further experiments, we believe that AQP4 would be a target to prevent and reduce PTBE around meningiomas in the future.

ACKNOWLEDGMENTS

We thank Mr. Xiaoqiang Xia for his technical assistance and Mr. Balkrishna Shrestha for his English editorial assistance.

REFERENCES

- Bitzer M, Wockel L, Morgalla M, Keller C, et al. (1997a). Peritumoural brain oedema in intracranial meningiomas: influence of tumour size, location and histology. *Acta Neurochir.* 139: 1136-1142.
- Bitzer M, Wockel L, Luft AR, Wakhloo AK, et al. (1997b). The importance of pial blood supply to the development of peritumoural brain edema in meningiomas. *J. Neurosurg.* 87: 368-373.
- Bitzer M, Opitz H, Popp J, Morgalla M, et al. (1998). Angiogenesis and brain oedema in intracranial meningiomas: influence of vascular endothelial growth factor. *Acta Neurochir.* 140: 333-340.
- Campbell BA, Jhamb A, Maguire JA, Toyota B, et al. (2009). Meningiomas in 2009: controversies and future challenges. *Am. J. Clin. Oncol.* 32: 73-85.
- Ding YS, Wang HD, Tang K, Hu ZG, et al. (2008). Expression of vascular endothelial growth factor in human meningiomas and peritumoural brain areas. *Ann. Clin. Lab. Sci.* 38: 344-351.
- Goldman CK, Bharara S, Palmer CA, Vitek J, et al. (1997). Brain edema in meningiomas is associated with increased vascular endothelial growth factor expression. *Neurosurgery* 40: 1269-1277.
- Ide M, Jimbo M, Kubo O, Yamamoto M, et al. (1992). Peritumoural brain edema associated with meningioma-histological study of the tumor margin and surrounding brain. *Neurol. Med. Chir.* 32: 65-71.
- Jung JS, Bhat RV, Preston GM, Guggino WB, et al. (1994). Molecular characterization of an aquaporin cDNA from brain: candidate osmoreceptor and regulator of water balance. *Proc. Natl. Acad. Sci. U. S. A.* 91: 13052-13056.
- Kalkanis SN, Carroll RS, Zhang J, Zamani AA, et al. (1996). Correlation of vascular endothelial growth factor messenger RNA expression with peritumoural vasogenic cerebral edema in meningiomas. *J. Neurosurg.* 85: 1095-1101.
- Klatzo I (1994). Evolution of brain edema concepts. *Acta Neurochir. Suppl.* 60: 3-6.
- Machein MR and Plate KH (2000). VEGF in brain tumors. *J. Neurooncol.* 50: 109-120.
- Ng WH, Hy JW, Tan WL, Liew D, et al. (2009). Aquaporin-4 expression is increased in edematous meningiomas. *J. Clin. Neurosci.* 16: 441-443.
- Otsuka S, Tamiya T, Ono Y, Michiue H, et al. (2004). The relationship between peritumoural brain edema and the expression of vascular endothelial growth factor and its receptors in intracranial meningiomas. *J. Neurooncol.* 70: 349-357.
- Provias J, Claffey K, delAguila L, Lau N, et al. (1997). Meningiomas: role of vascular endothelial growth factor/vascular permeability factor in angiogenesis and peritumoural edema. *Neurosurgery* 40: 1016-1026.
- Saadoun S, Papadopoulos MC, Davies DC, Krishna S, et al. (2002). Aquaporin-4 expression is increased in oedematous human brain tumours. *J. Neurol. Neurosurg. Psychiatry* 72: 262-265.
- Tait MJ, Saadoun S, Bell BA and Papadopoulos MC (2008). Water movements in the brain: role of aquaporins. *Trends Neurosci.* 31: 37-43.
- Yoshioka H, Hama S, Taniguchi E, Sugiyama K, et al. (1999). Peritumoural brain edema associated with meningioma: influence of vascular endothelial growth factor expression and vascular blood supply. *Cancer* 85: 936-944.